



## Comparison the effectiveness of corticosteroid and pulsed radiofrequency in chronic shoulder pain

PRF to ACJ and subacromial area

Korgün Ökmen<sup>1</sup>, Burcu Metin Ökmen<sup>2</sup>

<sup>1</sup>Department of Anesthesiology and Reanimation, <sup>2</sup>Department of Physical Medicine and Rehabilitation, University of Health Sciences, Bursa Yuksek Ihtisas Training and Research Hospital, Bursa, Turkey

### Abstract

**Aim:** Acromioclavicular joint (ACJ) disorders are particularly common in patients with impingement syndrome. We aim to evaluate the effectiveness of corticosteroid (CS) injections and pulsed radiofrequency (PRF) therapies applied to the Acromioclavicular joint (ACJ) and the subacromial area in the long-term in patients with impingement syndrome. **Material and Method:** 40 patients were analyzed in 2 different groups; CS(n=20) and PRF(n=20). Pre-treatment (W0) and post-treatment follow-ups at one (W1), four (W4), 12 (W12) and 24 weeks (W24) were carried out using Visual Analogue Scale (VAS), Shoulder Pain And Disability Index (SPADI) scores and Beck Depression Inventory (BDI) Scale tests. **Results:** There was a statistically significant improvement in all the evaluation parameters at W1, W4, W12, and W24 compared to W0 in both groups ( $p<0.05$ ). The comparison of the groups with each other there was no statistically significant difference between the VAS, SPADI and BDI values at W1, W4, W12, W24 ( $p>0.05$ ). **Discussion:** Our study results showed that CS injections and PRF therapy applied to the ACJ and subacromial area were effective during six-month follow-up in patients with chronic shoulder pain due to impingement syndrome. But statistical significance superiority to each other was not determined.

### Keywords

Acromioclavicular Joint; Subacromial Area; Impingement Syndrome; Corticosteroid Injections; Pulsed Radiofrequency

DOI: 10.4328/JCAM.5511 Received: 13.11.2017 Accepted: 28.11.2017 Published Online: 28.11.2017 Printed: 01.01.2018 J Clin Anal Med 2018;9(1): 87-91  
Corresponding Author: Korgün Ökmen, Department of Anesthesiology and Reanimation, University of Health Sciences, Bursa Yuksek Ihtisas Training and Research Hospital, 16130 Bursa, Turkey. T.: +90 2242955000 F.: +90 2243605055 GSM: +905057081821 E-Mail: korgunokmen@gmail.com

## Introduction

Shoulder pain is one of the most common causes of pain in the musculoskeletal system [1]. Pain and restriction in active movements of the shoulder remarkably decreases the quality of life of patients [1]. Rotator cuff pathologies and impingement syndrome are the most common causes of shoulder pain [2]. ACJ is a small joint; however, it is an important part of the shoulder girdle complex [3]. Pain and restriction in the arm lifting and cross body movements can manifest [4]. The initial treatment of symptomatic ACJ disorders often involves conservative therapies. Physical therapy modalities, analgesics, non-steroid anti-inflammatory drugs (NSAIDs), and corticosteroid (CS) injections to the ACJ can be applied [5]. Corticosteroid injections are commonly used in the management of shoulder pain thanks to their potent anti-inflammatory effects and rapid response to injection [6]. However, the use of these injections is limited due to pain, vasovagal reactions, altered serum glucose levels, facial flushing, and systemic side effects such as osteoporosis [7]. In addition, there are some reports suggesting that CS injections should not be performed frequently due to local complications such as tendon ruptures [8]. The studies have shown that CS can reduce pain and increase the range of motion of the joint with sustainable effects in the long-term [5,9].

Pulsed radiofrequency (PRF) therapy has been reported to offer an effective and simple treatment method in the management of chronic shoulder pain, and a single session can provide pain relief for a long period, thereby, facilitating functional rehabilitation [10]. It has been considered a non-destructive therapy, which does not cause neural injury [11]. In addition, PRF has been reported to be a useful treatment option in patients who are unresponsive to conservative therapies or not suitable for surgical therapy or those who are willing to undergo non-surgical treatments for chronic shoulder pain [12]. Although there are numerous studies in the literature reporting good outcomes with PRF application to the suprascapular nerve in the management of chronic shoulder pain [13,14], no study using PRF to the subacromial area and ACJ is available. In this study, we aimed to compare the effectiveness of CS injections and PRF therapies applied to the ACJ and the subacromial area in the long-term.

## Material and Method

### Patient Selection

Medical charts of 65 patients who were admitted to the physical medicine and rehabilitation (PMR) and algology outpatient clinics of our hospital between January 2013 and December 2015 were retrospectively reviewed. The study protocol was approved by the institutional Ethics Committee (The decision number is 2011-KAEK-25 2016/15-03). The study was conducted in accordance with the principles of Declaration of Helsinki. Inclusion criteria were: patients with chronic shoulder pain due to impingement syndrome (diagnosed with both clinical examination findings and Magnetic Resonance Imaging (MRI)) (for >3 months), and those aged between 18 and 60 years, also patients who respond to the diagnostic block by using 3 ml prilocaine (more than 50% reduction in VAS scores).

Exclusion criteria were: patients who received PMR, injections or PRF therapy to the shoulder area in the past one year, the presence of malignancy, radicular pain and cervical myofascial

pain syndrome, history of acute trauma, previous history of fracture in the shoulder to be treated, previous surgery or metal implants to the affected shoulder, inflammatory rheumatic disease, uncontrolled arterial hypertension, metabolic syndrome, diabetes mellitus, mental retardation, use of antidepressants, and autoimmune diseases.

The present study examined 40 patients meeting the inclusion criteria were analyzed in 2 different groups; Group 1: CS (n=20) and Group 2: PRF (n=20). Pre-treatment (W0) and post-treatment follow-ups at one (W1), four (W4), 12 (W12) and 24 weeks (W24) were carried out using Visual Analogue Scale(VAS), Shoulder Pain And Disability Index (SPADI) scores and Beck Depression Inventory(BDI) Scale tests.

### Treatment Protocol

All invasive procedures were performed by the same physician. On the patient who was in prone position, the C-arm fluoroscopy was adjusted toward the lateral and cephalo-caudal direction until the ACJ was identified within sight. After cleaning the access site, local anesthesia was administered to the cutaneous and subcutaneous tissue using 3 ml prilocaine. A 22 G 10 cm needle was guided to ACJ under fluoroscopy (Figure 1).

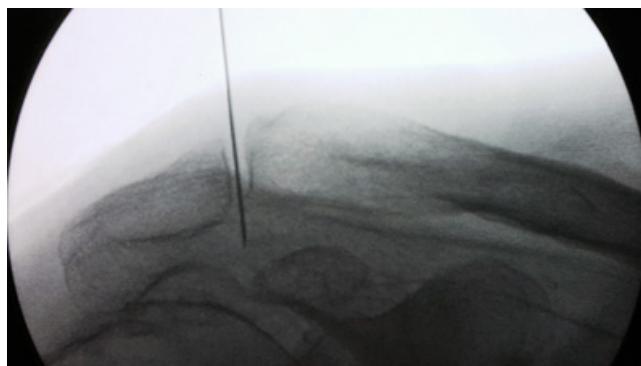


Figure 1. Anteroposterior C-arm fluoroscopic imaging; needle placement of ACJ and subacromial area.

Following;

### Pulsed Radiofrequency Procedure

PRF procedure was applied with 5 mm active-tip RF needle at 45 V, 200 ms, 42 OC for 120 s (2 min) ACJ and subacromial area 120 sn (2 min) (NeuroTherm, Middleton, MA, USA).

### Corticosteroid Protocol

A 3-ml of the mixture of bupivacaine 0.25% (4 mL) and methylprednisolone 40 mg (1mL) was administered to the subacromial area, and a 2-ml of the mixture was administered into the ACJ. In both groups, no posttreatment complications were observed during the follow-ups.

### Outcome Measures

The VAS score was used to evaluate the pain severity, the SPADI for to measure shoulder discomfort and BDI for to evaluate depression.SPADIs' evaluation includes two parts: pain and disability. Part 1 (shoulder pain index (SPI)) includes five questions in the pain subgroup and measures the pain experienced by the patient over the previous week using VAS (0 no pain, to 10 most severe pain). Part 2(shoulder disability index (SDI)) is the dis-

ability subgroup and includes eight questions and measures the degree of difficulty (0 no difficulty, to 10, requires help) in the shoulder movements of the patient during the last week. SPADI includes 13 questions, and zero point refers to maximal well-being, and 130 points refers to maximal sickness. We evaluated each part of the SPADI; SPI, SDI, and total SPADI separately. The validity of SPADI was demonstrated [15].

The Beck depression inventory (BDI) aims to measure behavioral findings of the depression in adults and adolescents. This inventory is composed of 21 items each ranked from mild to severe disease form. The patients are asked to mark the item that best fits their situation, and the total score is calculated by the sum of scores achieved in each item. 0-13 points indicate no depression, 14-19 points indicate mild depression, 20-28 points indicate moderate depression, and 29-63 points indicate severe depression. The total score on this scale is 63 points [16].

In addition, the patients did not receive any additional analgesic agents, PMR, or another intervention during follow-up.

### Statistical Analysis

Analysis of the collected data was performed using IBM SPSS 22.0 statistical package program. When the study data were evaluated, the Pearson chi square ( $\chi_2$ ) or Yates  $\chi_2$  tests were used in the comparison of the qualitative variables, in addition to descriptive statistical methods (frequency, percentage, mean and standard deviation). Normal distribution of the data was tested using Shapiro-Wilk test. Independent Samples t-test (t-test for independent groups) was used in between-groups comparisons while variables were found normally distributed. When a normal distribution was not found, the Wilcoxon signed rank test for group comparisons and Mann Whitney U test for comparisons between groups were used. Variance analysis with repeated measurement (ANOVA) was used in in-group comparisons. Values with a probability of (P)  $\alpha < 0.05$  was accepted as significant.

### Results

Of 40 patients, 14 were males, and 26 were females. There was no statistically significant difference between the two groups concerning age, gender, body mass index (BMI), duration of pain, side and week 0 (W0) values of VAS, SPI, SDI, SPADI and BDI ( $p < 0.05$ ) (Table 1). There was a statistically significant improvement in all the evaluation parameters at W1, W4, W12, and W24 compared to W0 in both groups ( $p < 0.05$ ) (Table 2).

The comparison of the groups with each other there was no statistically significant difference between the VAS, SPI, SDI, SPADI and BDI values at W1, W4, W12, W24 ( $p > 0.05$ ) (Table 2).

### Discussion

Although the present study showed significantly successful outcomes with both procedures, compared to baseline values, there was no statistically significant difference in the outcomes at W0, W1, W4, W12, and W24 follow-up visits between the two groups.

Impingement syndrome accounts for 44 to 65% of patients with chronic shoulder pain [17]. Initial therapy in impingement syndrome involves a conservative approach, whereas CS injections are commonly used [5]. Many studies have attempted to reveal the efficacy of CS injections commonly used in the management of chronic shoulder pain [18,19]. Among these studies, Göksu et al. included 61 patients in their study in which one group received triamcinolone acetonide + bupivacaine injection to the subacromial area, while the other group received Kinesio-taping three times with three days off [19]. The patients were assessed using the VAS, Passive range of motion (PROM), and SPADI. The authors found a statistically significant difference in the efficacy of CS injections at 4 weeks after therapy. Similarly,

Table 1. Comparison of the demographic characteristics of the patients, W0 VAS, SPI, SDI, SPADI and Beck Depression scale.

		Group1 (n=20)	Group2 (n=20)	p
Age		55.2±7.18	52.4±8.39	0.264
Gender	Female	12(%60)	14(%70)	0.602
	Male	8(%40)	6(%30)	
BMI(kg/m <sup>2</sup> )		28.82(21.46-35.16)	28.33(22.09-35.16)	0.883
Duration of pain		14(7-25)	17(9-24)	0.114
Affected Side	Right	13(%65)	12(%60)	0.799
	Left	7(%35)	8(%40)	
VAS		61(21-84)	62.5(19-82)	0.989
SPI		37.5(21-52)	36(19-48)	0.799
SDI		46(26-73)	48(28-75)	0.698
SPADI		87(47-125)	88.5(47-123)	0.862
BDI		20(7-30)	22(9-34)	0.301

Group 1: Corticosteroid group and Group 2: Pulsed Radiofrequency group. W0: week 0, VAS: Visual Analog Scale, BMI: Body Mass Index, SPI: Shoulder Pain Index, SDI: Shoulder Disability Index, SPADI: Shoulder Pain And Disability Index, BDI: Beck Depression Inventory

Table 2. Comparison of the W0, W1, W4, W12 and W24 VAS, SPI, SDI, SPADI and BDI values of study and control groups.

		W1 (1)	W4(2)	W12 (3)	W24 (4)	p**(1)	Difference
VAS	Group 1	20.5(9-38)	13.5(4-65)	20.5(10-43)	20.5(8-40)	<0.001	W0 between 1,2,3,4
	Group 2 p*	21(8-40) 0.967	14.5(0-61) 0.903	21.5(8-40) 0.775	20(6-35) 0.755	<0.001	W0 between 1,2,3,4
SPI	Group 1	10.5(4-41)	10(1-41)	12.5(3-37)	12(3-39)	<0.001	W0 between 1,2,3,4
	Group 2 p*	11.5(3-39) 0.765	10(2-38) 0.568	13.5(2-39) 0.625	12(4-35) 0.924	<0.001	W0 between 1,2,3,4
SDI	Group 1	13.5(3-48)	7(1-48)	14(4-45)	13.5(1-47)	<0.001	W0 between 1,2,3,4
	Group 2 p*	12.5(1-47) 0.664	9(0-53) 0.881	15(2-47) 0.349	14(1-42) 0.635	<0.001	W0 between 1,2,3,4
SPADI	Group 1	25.5(7-49)	17(2-89)	27(7-82)	26.5(6-86)	<0.001	W0 between 1,2,3,4
	Group 2 p*	23(6-86) 0.745	19.5(2-91) 0.755	27(8-86) 0.489	26.5(8-77) 0.704	<0.001	W0 between 1,2,3,4
BDI	Group 1	17.5(6-28)	13.5(4-19)	11(3-16)	7(1-13)	<0.001	W0 between 1,2,3,4
	Group 2 p*	20(7-32) 0.167	14.5(4-22) 0.464	12(4-18) 0.243	9(2-16) 0.059	<0.001	W0 between 1,2,3,4

Group 1: Corticosteroid group, Group 2: Pulsed Radiofrequency group. W0: week 0, W1: week 1, W4: week 4, W12: week 12, W24: week 24, VAS: Visual Analog Scale, SPI: Shoulder Pain Index, SDI: Shoulder Disability Index, SPADI: Shoulder Pain And Disability Index, BDI: Beck Depression Inventory

another study evaluated the outcomes of CS injections to the subacromial area under the guidance of ultrasonography, and the authors reported that this approach was effective in the short-term at 6 weeks during follow-up [18].

Furthermore, several studies have addressed possible local and systemic side effects of CS injections to the subacromial area [7,20,21]. In a study, Hong et al. showed no statistically significant difference between 20 mg and 40 mg doses and concluded that preferred use of a low dose at the initial stage [20]. In another study, 40 patients were divided into two groups: Group 1 received tenoxicam injections to the subacromial area once weekly for three weeks, and Group 2 received a single dose of methylprednisolone to the subacromial area. Both groups showed that these therapies were effective. However, the authors recommended tenoxicam as the first-line therapy thanks to its superior safety profile [21]. In the present study, patients who were considered to have a higher risk due to side effects of CS were excluded, and patients included in the study received a single CS injection.

Often subacromial area is evaluated in the impingement syndrome, and the therapy is directed to this area. It has been reported that rotator cuff problems can be avoided if ACJ OA is treated in the early period. In the study by Hossain et al. which evaluated the efficacy of CS injections to the ACJ, 25 patients with primary ACJ OA received intra-articular CS injections and were followed for five years [9]. The authors reported that CS injections in the treatment of primary isolated ACJ OA had prolonged effects sustaining up to 12 months. In another study, 58 patients with isolated ACJ symptoms received lidocaine + CS injection. In the study above, favorable outcomes at one month were observed in 28% of the patients. The patients who benefited from the injections were also followed for 42 months, and favorable outcomes were sustained in the long-term in most cases [5]. The present study attempted to increase the efficacy of therapy using injections to the subacromial area and ACJ in patients with chronic shoulder pain due to impingement syndrome.

Furthermore, as a novel treatment modality, PRF therapy is commonly used in the management of pain in today's practice. It is a non-neurolytic, effective, and easily applicable method which offers long-term relief with a single session of therapy [10,11]. This type of therapy to the nerves has also been reported to stimulate nociceptive nerve endings and, thereby, prolonged depression in the first synapses. In addition, PRF therapy has been suggested to increase the production of anti-inflammatory cytokines by producing an electric field on the immune cells, and progression of this process is regulated by increasing levels of pro-inflammatory cytokines such as interleukin (IL)-1b, tumor necrosis factor-alpha (TNF- $\alpha$ ), and IL-6 [8]. However, intra-articular use of PRF therapy in pain management is limited to case reports in the literature [8,22]. In a report of three cases who received therapy to the glenohumeral joint, Ozyuvaci et al. reported PRF therapy as a recommendable treatment modality [22].

In addition, PRF studies in the management of chronic shoulder pain often evaluated the application to the suprascapular nerve rather than application into and around the joints [14,23]. In a series of 40 patients who received PRF therapy to the su-

prascapular nerve due to impingement syndrome, the patients were evaluated using the Likert scale and Oxford Shoulder Score for six months, and it was found to be an effective treatment modality and the effects of this therapy were sustained in the long term [14]. In another study including 57 patients with chronic shoulder pain resistant to medical treatment, PRF was applied to the suprascapular nerve for 480 seconds, indicating a statistically significant recovery during follow-up [23].

Moreover, in a randomized controlled trial carried out by Gofeld et al. in 22 patients with chronic shoulder pain, the first group received lidocaine and the second group received lidocaine + PRF therapy to the suprascapular nerve during a six-month follow-up [24]. The authors reported significantly better outcomes in the PRF group. Another study which induced lesion using PRF to the suprascapular nerve under fluoroscopy in 13 patients with chronic shoulder pain showed that this therapy could be a potential treatment option in patients suffering from chronic shoulder pain, provided long-term pain control, and reduced the amount of analgesics [25].

In the present study, PRF therapy was applied to the subacromial area and ACJ. The success of the present study can be attributed to the effects of therapy on nerve endings in the ACJ and subacromial area. The discussion in this manuscript was limited due to lack of studies in the literature that evaluated the application of this therapy to the subacromial area and ACJ.

#### **Limitation**

Small sample size and lack of a placebo group were the main limitations of the present study.

#### **Conclusion**

In conclusion, our study results showed that CS injections and PRF therapy applied to the ACJ and subacromial area were effective during six-month follow-up in patients with chronic shoulder pain due to impingement syndrome. But statistical significance superiority to each other was not determined.

#### **Scientific Responsibility Statement**

*The authors declare that they are responsible for the article's scientific content including study design, data collection, analysis and interpretation, writing, some of the main line, or all of the preparation and scientific review of the contents and approval of the final version of the article.*

#### **Animal and human rights statement**

*All procedures performed in this study were in accordance with the ethical standards of the institutional and/or national research committee and with the 1964 Helsinki declaration and its later amendments or comparable ethical standards. No animal or human studies were carried out by the authors for this article.*

#### **Funding**

**None**

#### **Conflict of interest**

*None of the authors received any type of financial support that could be considered potential conflict of interest regarding the manuscript or its submission.*

## References

1. Armstrong A. Evaluation and management of adult shoulder pain: a focus on rotator cuff disorders, acromioclavicular joint arthritis, and glenohumeral arthritis. *Med Clin North Am.* 2014; 98 (4): 755-75.
2. Frost A, Robinson CM. The painful shoulder. *Surg. Oxf.* 2006; 24 (11): 363-7.
3. McDonald S, Hopper MA. Acromioclavicular joint disease. *Semin Musculoskelet Radiol.* 2015; 19(3): 300-6.
4. Mall NA, Foley E, Chalmers PN, Cole BJ, Romeo AA, Bach Jr BR. Degenerative joint disease of the acromioclavicular joint: a review. *Am J Sports Med.* 2013; 41 (11): 2684-92.
5. Van Riet RP, Goehre T, Bell SN. The long-term effect of an intra-articular injection of corticosteroids in the acromioclavicular joint. *J Shoulder Elbow Surg.* 2012; 21(3): 376-9.
6. Sabeti-Aschraf M, Ochsner A, Schueller-Weidekamm C, Schmidt M, Funovics PT, Skrbensky G, et al. The infiltration of the AC joint performed by one specialist: Ultrasound versus palpation a prospective pilot study. *Eur J Radiol.* 2010; 75 (1): 37-40.
7. Yoon SH, Lee HY, Lee HJ, Kwack KS. Optimal dose of intra-articular corticosteroids for adhesive capsulitis: a randomized, triple-blind, placebo-controlled trial. *Am J Sports Med.* 2013; 41(5): 1133-9.
8. Sluifster ME, Teixeira A, Serra V, Balogh S, Schianchi P. Intra-articular application of pulsed radiofrequency for arthrogenic pain- report of six cases. *Pain Pract.* 2008; 8(1): 57-61.
9. Hossain S, Jacobs LG, Hashmi R. The long-term effectiveness of steroid injections in primary acromioclavicular joint arthritis: a five-year prospective study. *J Shoulder Elbow Surg.* 2008; 17(4): 535-8.
10. Rohof OJ. Pulsed radiofrequency of peripheral nerves. *Pain Pract.* 2002 (3): 2: 257-60.
11. Van Zundert J, Raj P, Erdine S, van Kleef M. Application of radiofrequency treatment in practical pain management: state of the art. *Pain Pract.* 2002; 2(3): 269-78.
12. Lipov EG, Navaie M, Rothfeld C, Kelzenberg B, Sharghi LH, Solomon DJ, et al. Use of intra-articular and intrabursal pulsed radiofrequency for the treatment of persistent arthrogenic shoulder pain. *Pain Med.* 2013; 14(4): 554-6.
13. Eyigor C, Eyigor S, Korkmaz OK, Uyar M. Intra-articular corticosteroid injections versus pulsed radiofrequency in painful shoulder: a prospective, randomized, single-blinded study. *Clin J Pain.* 2010; 26 (5): 386-92.
14. Keskinbora K, Aydinli I. Long-term results of suprascapular pulsed radiofrequency in chronic shoulder pain. *Agri.* 2009; 21(1): 16-21.
15. MacDermid JC, Solomon P, Prkachin K. The Shoulder Pain and Disability Index demonstrates factor, construct and longitudinal validity. *BMC Musculoskelet Disord.* 2006; 7(1):12
16. Guy W. *Clinical Global Impressions: ECDEU Assessment Manual for Pharmacology*, revised edition. Rockville, MD: National Institute of Mental Health, Dept. of Health, Education and Welfare Publication (ADM). 1976; 18-22.
17. Van der Windt DA, Koes BW, De Jong BA, Bouter LM. Shoulder disorders in general practice: incidence, patient characteristics, and management. *Ann Rheum Dis.* 1995;54(12): 959-64.
18. Dogu B, Yucel SD, Sag SY, Bankaoglu M, Kuran B. Blind or ultrasound-guided corticosteroid injections and short-term response in subacromial impingement syndrome: a randomized, double-blind, prospective study. *Am J Phys Med Rehabil.* 2012; 91(8): 658-65.
19. Göksu H, Tuncay F, Borman P. The comparative efficacy of kinesiotaping and local injection therapy in patients with subacromial impingement syndrome. *Acta Orthop Traumatol Turc.* 2016; 50(5): 483-8.
20. Hong JY, Yoon SH, Moon DJ, Kwack KS, Joen B, Lee HY. Comparison of high and low dose corticosteroid in subacromial injection for periarticular shoulder disorder: a randomized, triple-blind, placebo-controlled trial. *Arch Phys Med Rehabil.* 2011; 92 (12): 1951-60.
21. Cift H, Ozkan FU, Tolu S, Seker A, Mahirogullari M. Comparison of subacromial tenoxicam and steroid injections in the treatment of impingement syndrome. *Ekleml Hastalik Cerrahisi.* 2015; 26(1): 16-20.
22. Ozyuvaci E, Akyol O, Acikgoz A. Intraarticular pulsed mode radiofrequency lesioning of glenohumeral joint in chronic shoulder pain: 3 cases. *Korean J Pain.* 2011; 24(4): 239-41.
23. Luleci N, Ozdemir U, Dere K, Toman H, Luleci E, Irban A. Evaluation of patients' response to pulsed radiofrequency treatment applied to the suprascapular nerve in patients with chronic shoulder pain. *J Back Musculoskelet Rehabil.* 2011; 24(3): 189-94.
24. Gofeld M, Restrepo Garces CE, Theodore BR, Faclier G. Pulsed radiofrequency of suprascapular nerve for chronic shoulder pain: a randomized double-blind active placebo-controlled study. *Pain Pract.* 2013; 13 (2): 96-103.
25. Liliang PC, Lu K, Liang CL, Tsai YD, Hsieh CH, Chen HJ. Pulsed radiofrequency lesioning of the suprascapular nerve for chronic shoulder pain: a preliminary report. *Pain Med.* 2009; 10(1): 70-5.

## How to cite this article:

Ökmen K, Ökmen BM. Comparison the effectiveness of corticosteroid and pulsed radiofrequency in chronic shoulder pain. *J Clin Anal Med* 2018;9(1): 87-91.